CONTENTS

Associate Editors v
Preface vii

SECTION I: BASICS

CHAPTER
1 Surgical Technique 3
2 Anesthesia 5
3 Preoperative Preparation and Postoperative Care 7
4 Ambulatory Surgery 11
5 Principles of Acute Care Surgery 13
6 Principles of Oncologic Surgery 15

SECTION II: SURGICAL ANATOMY

CHAPTER
7 Arterial Blood Supply to the Upper Abdominal Viscera 18
8 Venous and Lymphatic Supply to the Upper Abdominal Viscera 20
9 Anatomy of the Large Intestine 22
10 Anatomy of the Abdominal Aorta and Inferior Vena Cava 24
11 Thoracic and Pulmonary Anatomy 26

SECTION III: GENERAL ABDOMEN AND THORAX

CHAPTER
12 Laparotomy 30
13 Hasson Open Technique for Laparoscopic Access 38
14 Veress Needle Technique 40
15 Diagnostic Laparoscopy 42
16 Chronic Ambulatory Peritoneal Dialysis Catheter Insertion 44
17 Thoracotomy Incision 46
18 Thoracoscopy 50
19 Robotics in Abdominal Surgery: Room Setup and Docking 52

SECTION IV: ESOPHAGUS AND STOMACH

CHAPTER
20 Gastrostomy 58
21 Percutaneous Endoscopic Gastrostomy 60
22 Closure of Perforated Duodenal Ulcer 62
23 Gastrojejunostomy 66
24 Pyloroplasty and Gastroduodenostomy 70
25 Vagotomy 72
26 Vagotomy, Subdiaphragmatic Approach 74
27 Hemigastrectomy, Billroth I Method 78
28 Hemigastrectomy, Billroth I Stapled 82
29 Gastrectomy, Subtotal 86
30 Gastrectomy, Subtotal—Omentectomy 94
31 Gastrectomy, Polya Method 96
32 Gastrectomy, Hofmeister Method 98
33 Hemigastrectomy, Billroth II Stapled 100
34 Total Gastrectomy 102
35 Total Gastrectomy, Stapled 114
36 Roux-en-Y Gastrojejunostomy 118
37 Fundoplication 122
38 Fundoplication, Laparoscopic 126
39 Paraesophageal Hernia, Laparoscopic and Robotic 130
40 Esophageal Myotomy, Laparoscopic 134
41 Roux-en-Y Gastric Bypass, Laparoscopic 136
42 Sleeve Gastrectomy, Laparoscopic 140
43 Adjustable Gastric Band, Laparoscopic 142
44 Esophagectomy, Transhiatal 144
45 Esophagectomy, Transthoracic 154
46 Pyloromyotomy 156

SECTION V: SMALL INTESTINE, COLON, AND RECTUM

CHAPTER
47 Intussusception and Meckel's Diverticulectomy 160
48 Resection of Small Intestine 162
49 Resection of Small Intestine, Stapled 164
50 Enteroenterostomy, Stapled 168
51 Enterostomy 170
52 Appendectomy 172
53 Appendectomy, Laparoscopic 176
54 Surgical Anatomy for Resection of the Colon and Rectum 180
55 Loop Ileostomy 182
56 Transverse Colostomy 184
57 Closure of Colostomy 186
58 Parastomal Hernia Repair, Laparoscopic 188
59 Colon Anastomosis, Stapled 192
60 Colectomy, Right 194
61 Colectomy, Right, Laparoscopic 198
62 Colectomy, Left, End-to-End Anastomosis 200
63 Sigmoidectomy, Laparoscopic 204
64 Abdominoperineal Resection 208
65 Total Colectomy and Total Proctocolectomy 220
66 Low Anterior Resection 230
67 Low Anterior Resection, Robotic 238
68 Ileoanal Anastomosis 244
69 Rectal Prolapse, Perineal Repair 250
70 Rubber Banding and Excision of Hemorrhoids 256
71 Perirectal Abscess, Fistula-in-Ano, and Anal Fissure 260
72 Excision of Pilonidal Sinus 266

SECTION VI: GALLBLADDER, BILE DUCTS, AND LIVER

CHAPTER
73 Cholecystectomy, Laparoscopic 270
74 Open Cholecystectomy 276
75 Common Bile Duct Exploration, Open 284
76 Common Bile Duct Exploration, Transduodenal Technique 286
77 Choledochoduodenostomy 288
78 Cholecystectomy, Subtotal 290
79 Cholecystostomy 292
80 Roux-en-Y Hepaticojejunostomy 294
81 Biopsy of Liver, Open 300
82 Anatomy and Resections of the Liver 302
83 Local Resection of Hepatic Tumor, Nonanatomic 304
84 Right Hepatectomy (Segments 5–8) 306
85 Left Hepatectomy (Segments 2–4) 310
86 Extended Right Hepatectomy (Segments 4–8 ± Segment 1) 314

SECTION VII: PANCREAS AND SPLEEN

CHAPTER
87 Drainage of Cyst or Pseudocyst of the Pancreas 322
88 Pancreaticojejunostomy (Puestow–Gillesby Procedure) 328
89 Resection of the Tail of the Pancreas 340
90 Resection of the Tail of the Pancreas with Splenic Preservation, Laparoscopic 346
91 Resection of the Tail of the Pancreas and Spleen, Robotic 348
92 Pancreaticoduodenectomy (Whipple Procedure) 350
93 Total Pancreatectomy 368
94 Splenectomy 374
95 Splenectomy, Laparoscopic 380
96 Splenic Conservation 384

www.pbadisteb.pub

SECTION VIII: GENITOURINARY AND RENAL TRANSPLANTATION

CHAPTER
97 A Gynecologic Procedures Overview 391
98 Total Abdominal Hysterectomy 392
99 Salpingectomy—Oophorectomy 396
100 Gynecologic System: Routine for Vaginal Procedures 398
101 Diagnostic Techniques for Cervical Lesions and Dilatation and Curettage 400
102 Ureteral Injury Repair 402
103 Donor Nephrectomy, Laparoscopic 404
104 Kidney Transplant 408

SECTION IX: HERNIA

CHAPTER
105 Repair of Ventral Hernia, Laparoscopic 414
106 Open Repair of Ventral Hernia with Myofascial Release 418
107 Repair of Ventral Hernia with Bilateral Transversus Abdominis Release, Robotic 426
108 Repair of Umbilical Hernia 430
109 Repair of Inguinal Hernia (Tissue Repair) 432
110 Repair of Inguinal Hernia with Mesh (Modified Lichtenstein) 442
111 Repair of Inguinal Hernia with Mesh (Plug and Patch) 446
112 Repair of Femoral Hernia (Tissue Repair) 450
113 Repair of Femoral Hernia with Mesh 452
114 Laparoscopic Anatomy of the Inguinal Region 454
115 Repair of Inguinal Hernia, Laparoscopic Transabdominal Preperitoneal 456
116 Repair of Inguinal Hernia, Laparoscopic Totally Extraperitoneal (TEP) 458
117 Repair of Recurrent Inguinal Hernia, Robotic, Transabdominal Preperitoneal 460
118 Hydrocele Repair 462

SECTION X: ENDOCRINE

CHAPTER
119 Thyroidectomy, Subtotal 466
120 Parathyroidectomy 474
121 Open Adrenalectomy, Bilateral 478
122 Adrenalectomy, Left Laparoscopic 482
123 Adrenalectomy, Right Laparoscopic 484
124 Adrenalectomy, Left Robotic 486
125 Adrenalectomy, Right Robotic 488

SECTION XI: HEAD AND NECK

CHAPTER
126 Tracheotomy 492
127 Tracheotomy, Percutaneous Dilational 494
128 Radical Neck Dissection 498
129 Zenker's Diverticulectomy 506
130 Parotidectomy, Lateral Lobectomy 508

SECTION XII: SKIN, SOFT TISSUE, AND BREAST

CHAPTER
131 Sentinel Lymph Node Dissection, Melanoma 512
132 Breast Anatomy and Incisions 516
133 Total Mastectomy and Modified Radical Mastectomy 518
134 Sentinel Lymph Node Dissection, Breast 522
135 Axillary Dissection, Breast 526
136 Skin Graft 528

SECTION XIII: VASCULAR

CHAPTER
137 Carotid Endarterectomy 532
138 Vascular Access, Arteriovenous Fistula 538
139 Venous Access, Port Placement, Internal Jugular Vein 540
140 Venous Access, Central Venous Catheter, Subclavian Vein 542
141 Resection of Abdominal Aortic Aneurysm 544
142 Aortofemoral Bypass 552
143 Thromboembolectomy, Superior Mesenteric Artery 556
144 Femorofemoral Bypass 558
145 Femoropopliteal Reconstruction 560
146 Saphenous Vein In Situ Arterial Bypass 570
147 Thromboembolectomy, Femoral 574
148 Inferior Vena Cava Filter Insertion 576
149 Ablation of the Great Saphenous Vein, Endovascular 578
150 Shunting Procedures for Portal Hypertension 580
151 Endovascular, General Considerations and Room Setup 582
152 Abdominal and Thoracic Aortic Aneurysm, Endovascular 586
153 Resuscitative Endovascular Balloon Occlusion of the Aorta 590
154 Superficial Femoral Artery Interventions and Stenting 594
155 Iliac Artery Occlusive Disease, Endovascular Stenting 596

SECTION XIV: EXTREMITIES

CHAPTER
156 Fasciotomy 600
157 Escharotomy 602
158 Principles of Amputation 606
159 Amputation, Supracondylar 608
160 Incision and Drainage of Infections of the Hand 612
161 Suture of Tendon 614

Index 616

www.abadistan.pub

CHAPTER 22

Closure of Perforated Duodenal Ulcer

A. OPEN CLOSURE

INDICATIONS Perforation of an ulcer of the stomach or duodenum is a surgical emergency, but before performing the operation, sufficient time should be allowed for the patient to recover from the initial shock (rarely severe or prolonged) and for restoration of the fluid balance. The choice for closure of the perforation versus a definitive ulcer procedure depends on the overall assessment of risk factors by the surgeon. Laparoscopic exploration with or without definitive repair is often preferred, especially in the setting of anterior perforation of the duodenum, with a plan for simple closure.

PREOPERATIVE PREPARATION The patient may have a history of previous peptic ulcer and long-term use of nonsteroidal anti-inflammatory drugs (NSAIDs). An upright plain film may show free air. If the diagnosis is in question, an upper gastrointestinal series with water-soluble contrast material may be helpful. Time is of the essence in treatment, and prolonged workups should be avoided. The intravenous administration of an appropriate type and volume of fluid is necessary depending on the patient's general condition and the length of time that has elapsed since perforation. Parenteral administration of antibiotics and the institution of constant nasogastric suction are routine.

ANESTHESIA General endotracheal anesthesia combined with muscle relaxants is preferred.

POSITION The patient is placed in a comfortable supine position with the feet slightly lower than the head to assist in bringing the field below the costal margin and to keep gastric leakage away from the subphrenic area.

OPERATIVE PREPARATION A Foley catheter and orogastric or nasogastric tube are placed after induction of anesthesia. The skin is prepared in the usual manner. Sterile drapes are applied according to the surgeon's specifications. Then a time-out is performed.

INCISION AND EXPOSURE Because the majority of perforations occur in the anterosuperior surface of the first portion of the duodenum, a small, high midline incision is made. A culture of the peritoneal fluid is taken, and as much exudate as possible is removed by suction. The liver is held upward with retractors, exposing the most frequent sites of perforation. The site may be walled off with omentum if the perforation has been present for several hours; therefore, care is exercised in approaching the perforation to avoid unnecessary soiling.

www.abadisebook

DETAILS OF THE PROCEDURE The easiest method of closure consists of placing three sutures of fine silk through the submucosal layer on one side with extension through the region of the ulcer and then out a corresponding distance on the other side of the ulcer (FIGURE 1). Starting at the top of the ulcer, the sutures are tied very gently to prevent laceration of the friable tissues. The long ends are retained (FIGURE 2). The closure is reinforced with omentum by separating the long ends of the three previously tied sutures and placing a small portion of omentum along the suture line. The ends of these sutures are loosely tied, anchoring the omentum over the site of the ulcer (FIGURE 3).

The tissue may be so indurated that the ulcer cannot be closed successfully, making it necessary to seal the perforation by anchoring omentum directly over the ulcer.

In the presence of a perforated gastric ulcer, the area surrounding the ulcer can be completely excised often with a stapler and sent for frozen-section analysis to exclude malignancy. This is determined by the site of ulcer perforation. Alternatively, a small biopsy of the margin of the perforation is taken because of the possibility of malignancy (FIGURES 4 and 5). The omentum may be anchored over the suture line (FIGURE 6). Closure of a gastric ulcer may be reinforced with a layer of interrupted silk serosal sutures because there is little danger of obstruction.

In the presence of perforation of an obvious carcinoma, resection is preferred, but in cases of high operative risk or metastatic disease requiring palliation, it may be acceptable to close the perforation, followed by resection upon recovery. If the patient's general condition is good and the perforation has lasted only a few hours, a gastric resection may be justified. Vagotomy and pyloroplasty or antrectomy for an early perforated duodenal ulcer in a good-risk patient is preferred by some surgeons.

CLOSURE All exudate and fluid are removed by suction. Repeated irrigation of the peritoneal cavity with saline should be considered when there is gross contamination by food particles. Drainage of the area of perforation may be performed with a closed suction area at the surgeon's preference. A temporary Stamm gastrostomy can be considered because prolonged obstruction of the pylorus may occur.

POSTOPERATIVE CARE The patient, when conscious, is placed in Fowler's position. Nasogastric suction can be employed for the first 24 hours or as needed. The fluid balance is maintained by intravenous infusions. Antibiotics are continued. Proton pump inhibitors should be given intravenously until nothing-by-mouth intake is started. Consideration should be given to eradicate *Helicobacter pylori* if present. Simple closure of the perforation has not cured the patient's ulcer or the patient's tendency to form another. It must be remembered that a subphrenic or pelvic abscess may complicate the postoperative period. CONTINUES

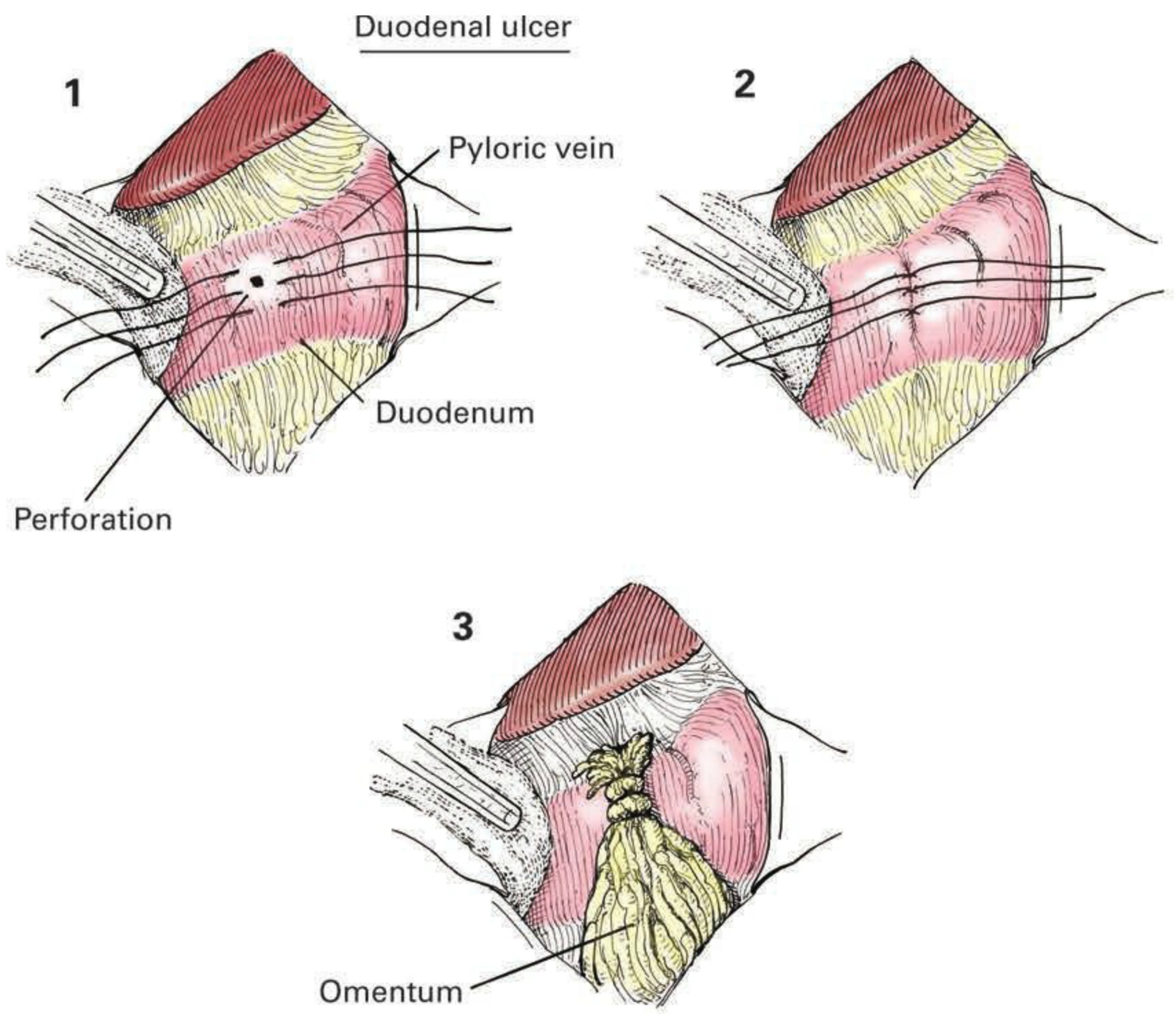

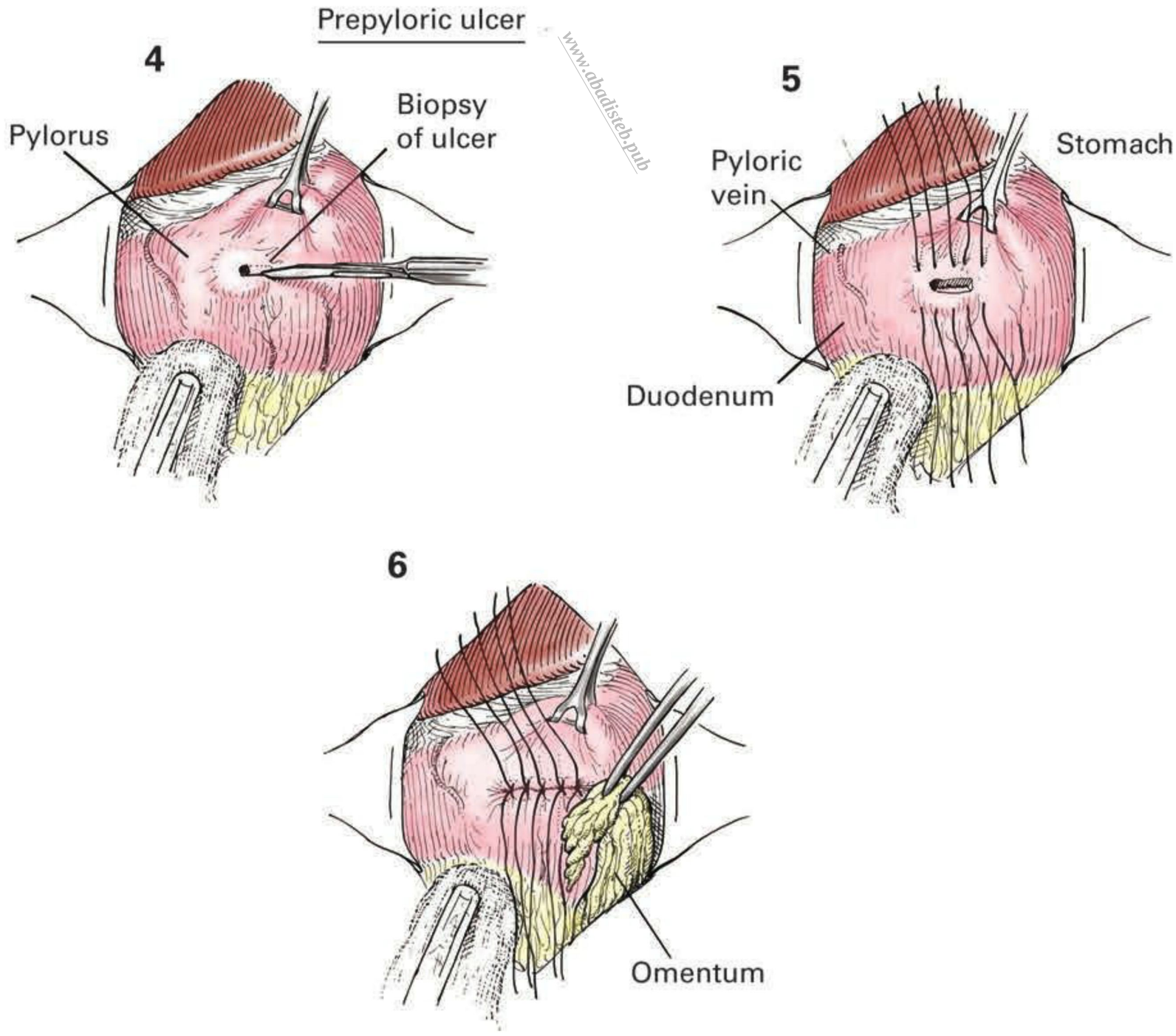

www.abadisteb.pub

B. LAPAROSCOPIC CLOSURE CONTINUED

INDICATIONS The laparoscopic approach is a suitable approach to open repair in many clinical situations. It should be avoided in septic patients whom are hemodynamically unstable and in patients with prior abdominal surgery.

ANESTHESIA See Section A.

POSITION The patient is placed in the supine modified lithotomy position (FIGURE 7). The surgeon stands between the patient's legs with the assistant on the patient's left side and the surgical assistant to the patient's right. The videoscopic monitors are placed above the patient's head on the right and left sides.

OPERATIVE PREPARATION See Section A.

DETAILS OF THE PROCEDURE Initial insufflation is accomplished with a Veress needle or Hasson trocar at the umbilicus. A three-trocar technique is used. A 10-mm cannula is placed at the umbilicus for the laparoscope. In larger patients, the camera port may need to be placed in the supraumbilical position (FIGURE 8). Two additional 5-mm ports are placed under direct vision (FIGURE 8), one in the right subcostal area in the midclavicular line. The second is placed in the subcostal region on the left in the midclavicular line. An additional port for placement of a Nathanson or articulating retractor to elevate the liver may be needed if the liver is adherent to the area of the perforation.

The patient is placed in a gentle reverse Trendelenburg position. The abdomen is thoroughly irrigated and examined to exclude other causes of pneumoperitoneum. Large perforations extending to the posterior duodenum and involving more than 50% of the circumference will be difficult to close laparoscopically, and conversion to an open operation may be considered. Gastric perforation should prompt consideration of gastric cancer. A biopsy may be indicated.

The perforation is closed with three or more nonabsorbable 3-0 sutures (FIGURE 9). These are placed at least 7 mm from the edge and tied as placed, leaving 3- to 4-cm-long, uncut tails (FIGURE 10). A portion of the omentum is laid over the ulcer closure and secured by tying the tails of the sutures over the omentum (FIGURE 11).

The area is irrigated with saline to remove any debris or bile. The closure may be assessed with installation of methylene blue into the orogastric or nasogastric tube. A closed suction drain may be placed at the surgeon's discretion.

POSTOPERATIVE CARE See Section A. ■

www.dbadisteb.pub

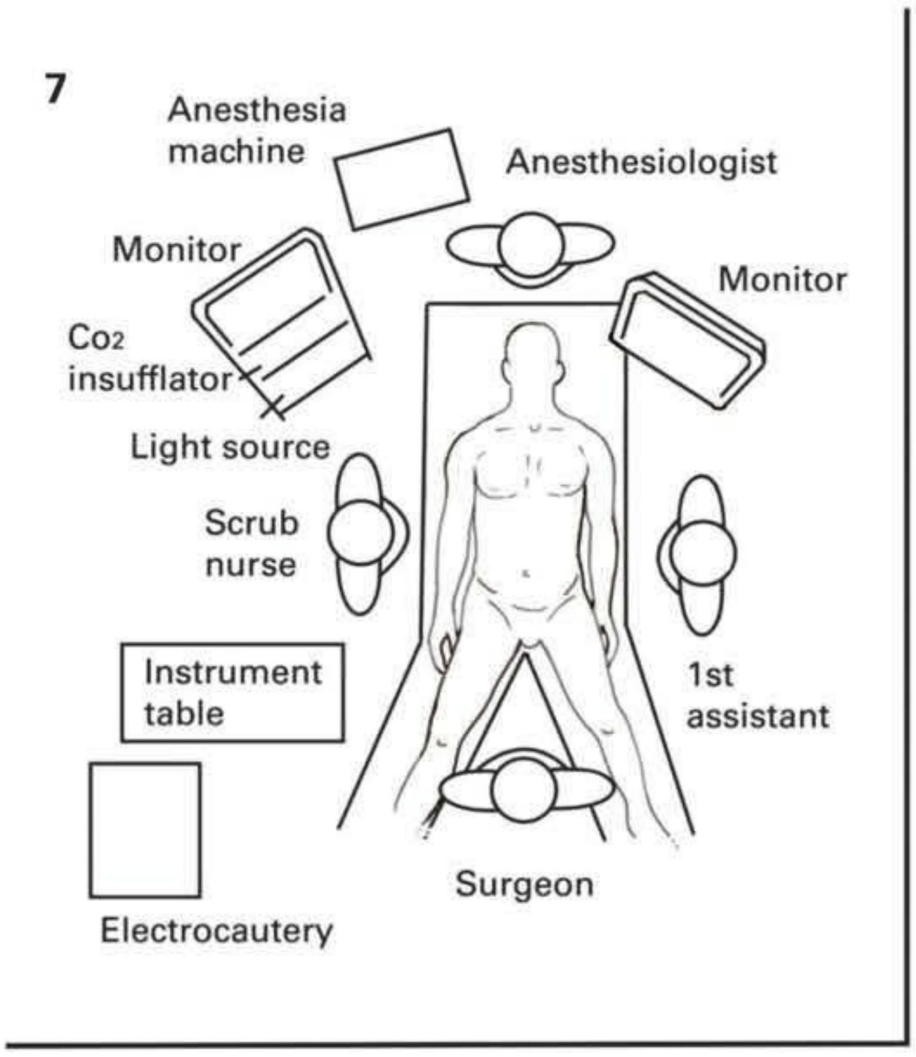

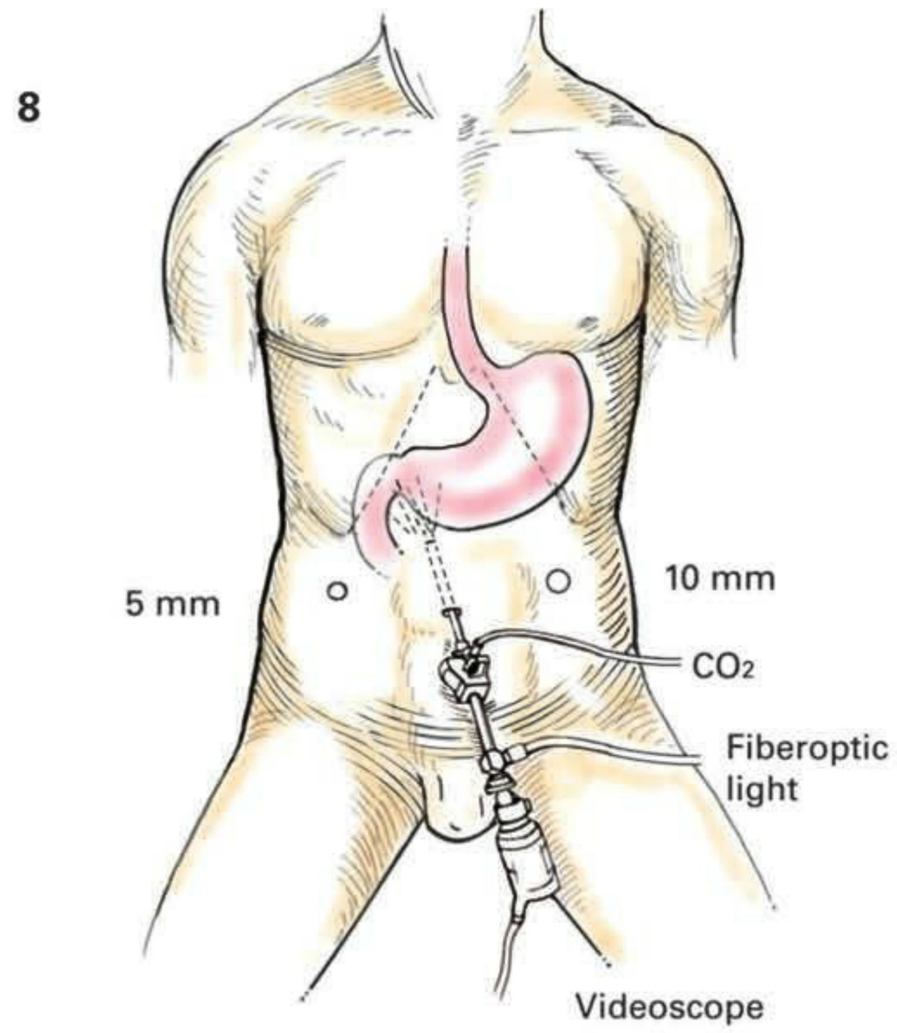

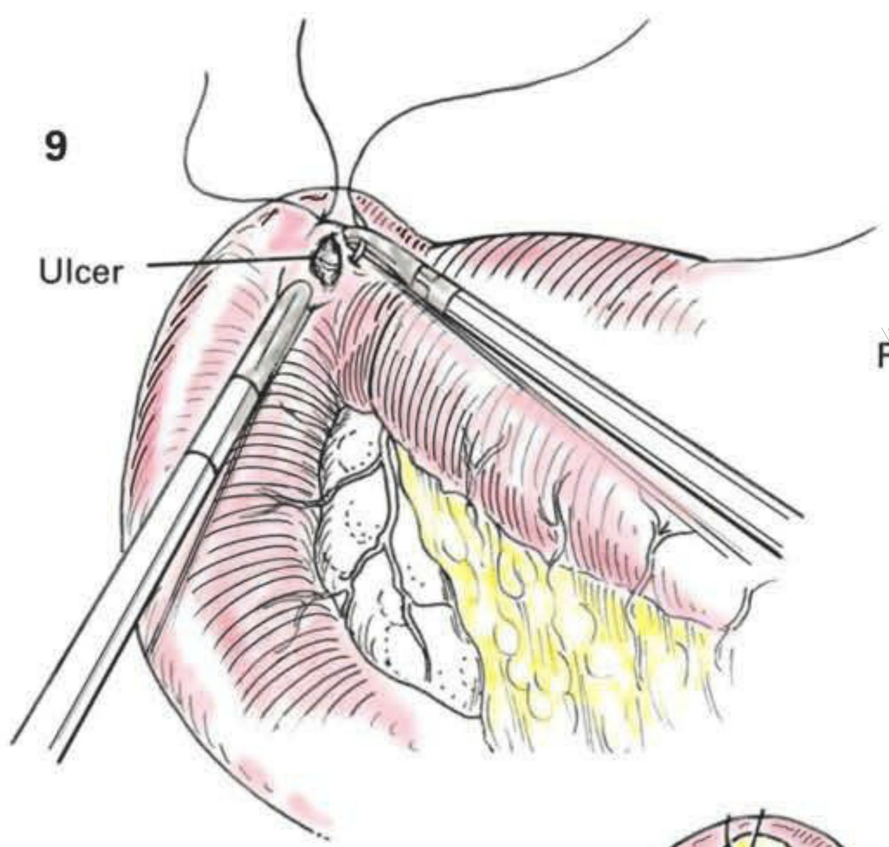

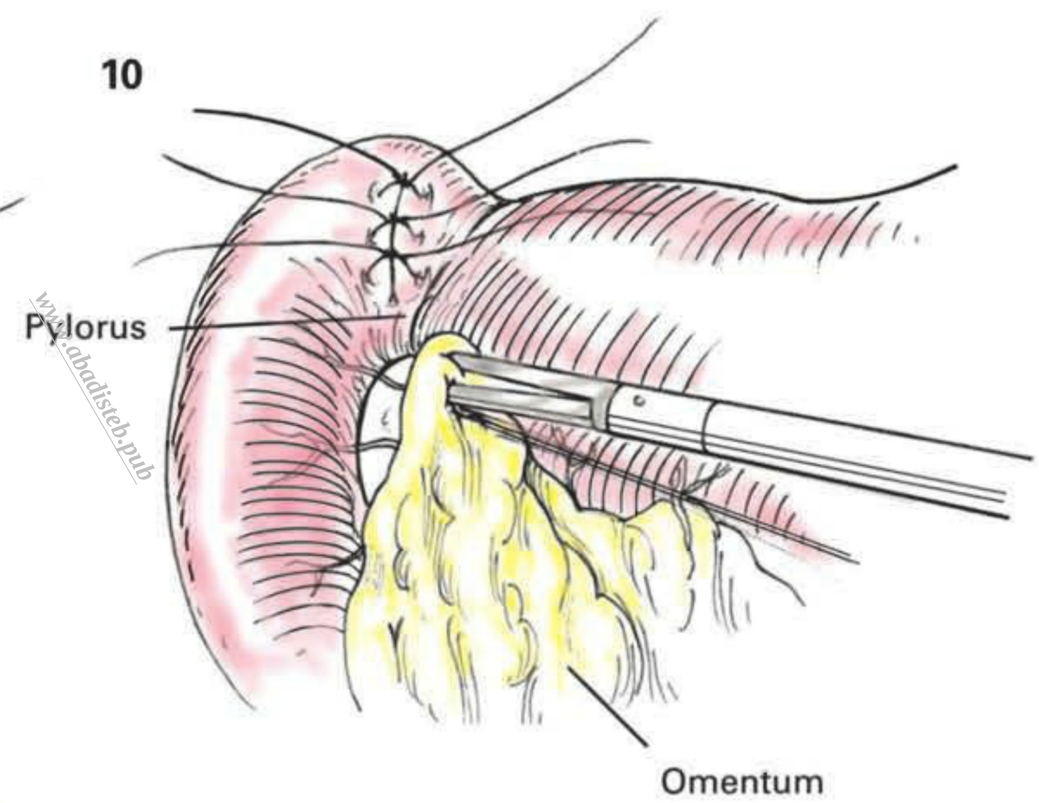
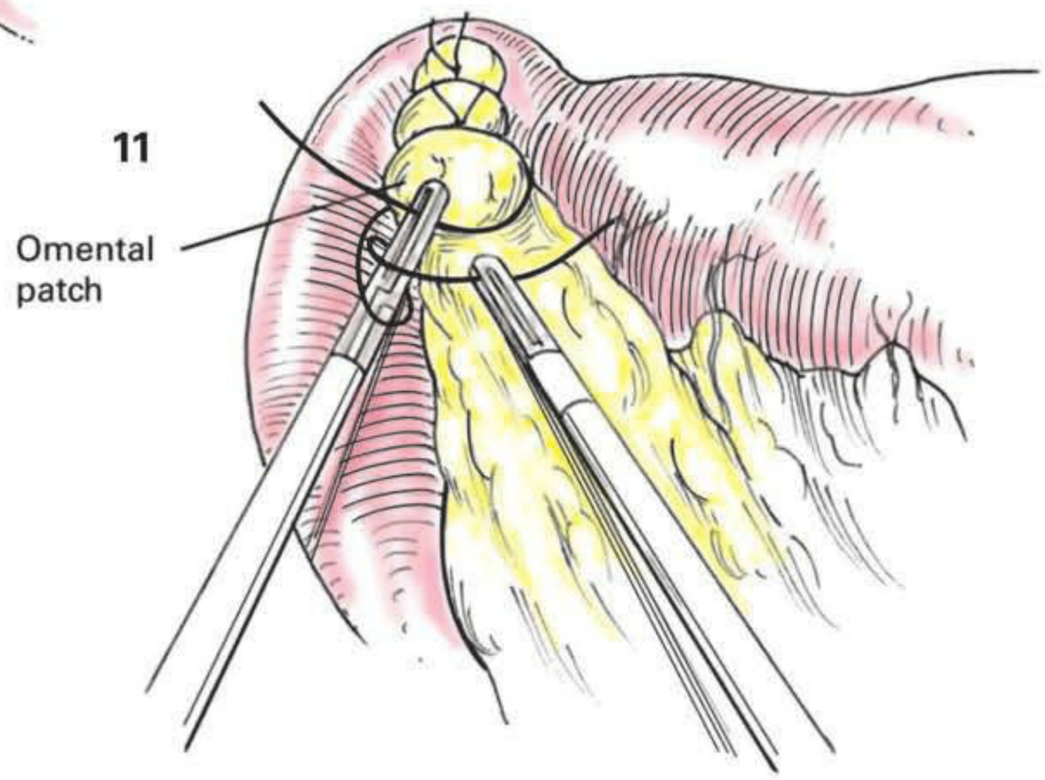
www.abadisteb.pub